

IMAGES IN CLINICAL MEDICINE

Carcinosarcoma of the Uterus Metastasizing to the Scalp

DOI: 10.7251/SMD1302095G

(Scr Med 2013;44:95)

UDK 6.

**Roberto Gianani¹,
Sumul Gandhi²,
Jennifer Bero¹**

¹Surgical Pathology Fellows, University of Illinois at Chicago and Stroger Hospital of Cook County, Surgical Pathology Fellowship Program, Chicago Illinois.

²Dermatopathology Fellow, Stroger Hospital of Cook County, Chicago, Illinois.

Correspondence

Jennifer Bero
Surgical Pathology Fellows
University of Illinois at Chicago,
Chicago, Illinois 60612 USA

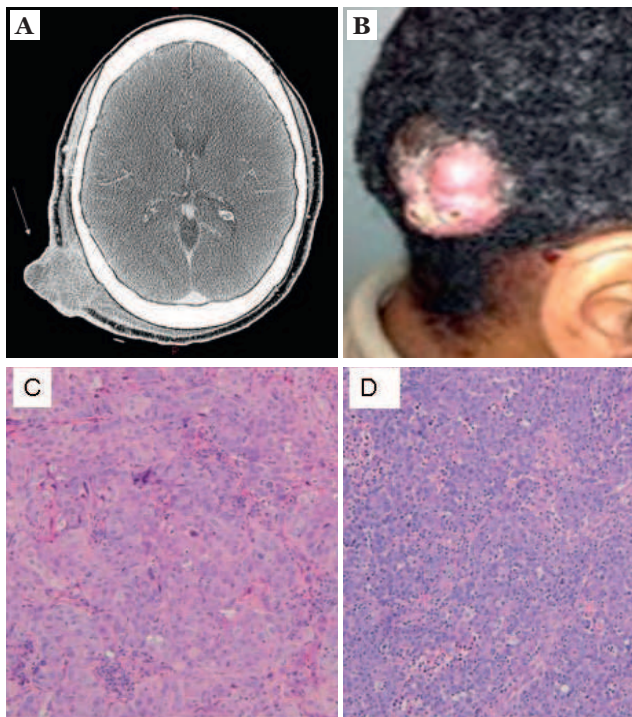


Figure 1. Morphologic and histologic presentation of the carcinosarcoma of the uterus metastasizing to the scalp. A. CT scan of the scalp; B. photograph of the scalp lesion; C. H&E stain of the scalp lesion (20 x magnification); D. H&E stain of the uterine tumor (20 x magnification).

A 56 year old G12P6066 post menopausal woman presented with progressive menorrhagia for three months and a scalp lesion (Figure 1, A and B). On evaluation of an endometrial biopsy a grade 2/3 endometrioid endometrial carcinoma was identified. A subsequent CT scan revealed a heterogeneous, enhancing soft tissue uterine mass.

Biopsy of the scalp lesion demonstrated a poorly differentiated carcinoma with positive immunohistochemical staining for CK7, EMA and focal positivity for ER and CA-125. A similar profile was seen in the previously biopsied endometrial lesion. Therefore metastasis of endometrial carcinoma to the scalp could not be excluded.

A hysterectomy was subsequently performed. On gross examination of the uterus, a 6.5 cm bulky, friable, exophytic endometrial mass was identified. Myometrial invasion was minimal. Microscopic examination revealed a carcinosarcoma with high grade epithelial component histologically similar to the scalp lesion (Figure 1, C and D). Focal sarcomatous elements within the uterine tumor were also present.

Carcinosarcomas of the uterus usually metastasize to the lung or peritoneum and to date this is only the second report in the english language literature of carcinosarcoma of the uterus metastasizing to the scalp (1).

Reference

1. Hamarech WA, Subhraleena D, Cherian SV, Vence T. Uterine Carcinosarcoma with scalp Metastasis: A rare presentation. Intern Med 51: 131, 2012.